

Imaging findings of Ovarian Adenofibroma in Multiparous Woman

SANGAVI JEYARAJ¹, JAYA SELIN PRAVEENA JOSEPH², ASHOK RANJAN³, SENTHIL KUMAR AIYAPPAN⁴

(CC) BY-NC-ND

Keywords: Benign, Cystadenofibroma, Follicular cyst

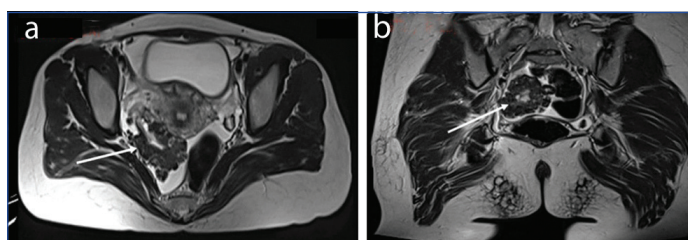
A 29-year-old married, non pregnant multiparous woman presented to the Gynaecological Outpatient Department (OPD) with complaints of bilateral dull, aching lower abdominal pain of one year's duration, more pronounced on the right side, which had aggravated over the past five days. There was no history of nausea or vomiting, and her menstrual cycle was regular, lasting three to four days every 28 days. She had a previous history of appendectomy eight months ago. Apart from this, her past medical history was unremarkable, and there was no family history of malignancy. Her general condition was fair, and her vitals were normal, with a blood pressure of 110/70 mmHg and a pulse rate of 82 beats per minute.

On examination of the abdomen, it was soft, and mild tenderness was noted over the right pelvic region with no palpable mass. On per speculum examination, the cervix appeared healthy. On pervaginal examination, the uterus was anteverted, and the bilateral fornices were free. An ultrasound was performed outside and demonstrated a relatively well-defined heterogeneous multicystic mass measuring approximately 5.2×4.8×4.4 cm in the right adnexa, while the right ovary could not be separately identified, suggesting a possible right ovarian origin with a follicular cyst in the left ovary measuring 1.7×1.5 cm.

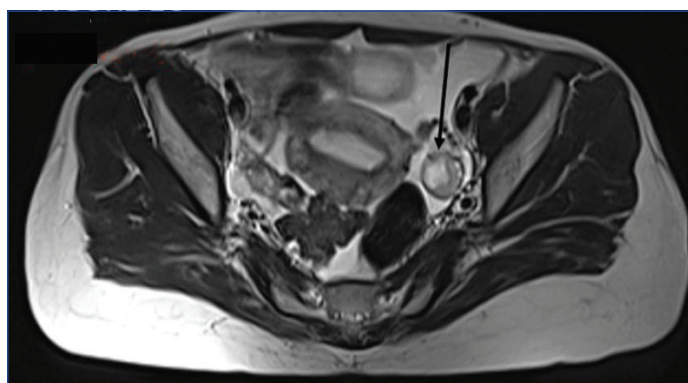
She was subjected to a Contrast-enhanced Computed Tomography (CECT) abdomen for evaluation and staging of the right ovarian mass. Magnetic Resonance Imaging (MRI) of the pelvis was also done to characterise the right ovarian mass and to rule out torsion, as there was no evidence of metastasis on the Computed Tomography (CT) scan. The MRI of the pelvis revealed an exophytic, cauliflower-like mass lesion measuring 5×5×4.8 cm arising from the right ovary. The mass appeared hypointense on T2-weighted images [Table/Fig-1a,b], and a T2 hyperintense cyst measuring approximately 1.7×1.5 cm was noted in the left ovary [Table/Fig-2]. The possibility of ovarian cystadenofibroma of the right ovary and a follicular cyst in the left ovary was considered based on the findings observed on MRI. CECT of the abdomen revealed a mildly enhancing, exophytic solid mass lesion with a lobulated contour, measuring approximately 5.1×4.7×4.6 cm, involving the right ovary [Table/Fig-3]. Her serum CA-125 was normal, with a value of 32.7 U/mL (normal: 0-35 U/mL). After confirming her fitness for anaesthesia, she was taken for a laparoscopic right salpingo-oophorectomy under general anaesthesia.

Intraoperative findings included a 4×4 cm cauliflower-like mass in the right ovary and a 1×1 cm cyst in the left ovary. The uterus and bilateral fallopian tubes were found to be normal, with no significant lymphadenopathy. A peritoneal wash was performed and sent for cytology, and the right ovary with the fallopian tube was sent for histopathological examination. There were no intraoperative complications, and the postoperative period was uneventful.

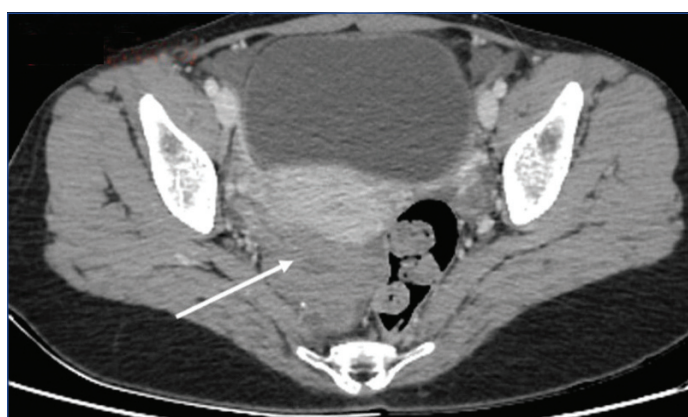
Histopathological examination of the right ovarian cauliflower-like growth revealed ovarian stroma with gland-like spaces lined by low cuboidal epithelium, which was compressed by dense fibrous stroma composed of spindle cells with bland nuclei, forming nodules with focal areas showing oedematous stroma and no



[Table/Fig-1]: a) Axial; and b) coronal section of T2-weighted image of MRI showing exophytic cauliflower-like hypointense mass arising from right ovary (white arrows).



[Table/Fig-2]: Axial section of T2-weighted image of MRI showing T2 hyperintense lesion in the left ovary - suggestive of follicular cyst (black arrow).



[Table/Fig-3]: Axial section of CECT abdomen scan showing mildly enhancing, exophytic solid mass lesion with lobulated contour involving the right ovary (white arrow).

evidence of atypia or malignancy. The histopathological features were suggestive of benign serous adenofibroma. The right fallopian tube was unremarkable, and the peritoneal wash fluid did not reveal any malignant cells. Since, adenofibroma is a benign lesion, she is kept under follow-up and is presently doing well.

Ovarian adenofibromas are rare benign tumours that contain epithelial and fibrous stromal components [1]. Ovarian adenofibromas are typically complex adnexal masses that contain septations, as well as both cystic and solid components [2]. The cystic, semisolid, or solid appearance of the tumour depends upon the amount and secretory

activity of the epithelial component and the amount of stromal components [1]. Ovarian adenofibromas can be asymptomatic or may sometimes present as a lump in the lower abdomen. In the present case, the patient experienced lower abdominal pain without any lump. Due to their solid component or irregular thick septa, these ovarian lesions are often misdiagnosed as malignant on preoperative imaging [1]. MRI is the investigation of choice for the preoperative assessment of ovarian masses because the very low signal intensity of T2-weighted MR images is suggestive of fibrous components, such as fibroma, fibrothecoma, and Brenner's tumour [1]. The cauliflower-like appearance of the lesion helped to identify the ovarian adenofibroma in present case, as it has been previously reported by Paul P et al., [1]. Radical surgery for the presumptive diagnosis of an ovarian malignancy based on gross appearance and radiology, especially in women of reproductive age, could prove to be devastating considering the benign nature of these tumours. Complete surgical removal of the tumour is the treatment of choice for ovarian adenofibromas [1]. Ovarian adenofibromas usually have a good outcome after surgery, documenting the benign nature of this tumour [3]. On ultrasound and CT, ovarian cystadenofibromas may appear as complex solid-cystic

masses and may be difficult to differentiate from malignancy [4]. On MRI, they show low signal intensity on T2-weighted sequences, as seen in the present case. The possibility of a benign tumour should be considered if the ovarian mass exhibits low signal intensity on T2-weighted images [5].

Ovarian cystadenofibromas are benign ovarian tumours with a very good prognosis after complete surgical removal. Being benign, the risk of recurrence is minimal after thorough surgical excision.

REFERENCES

[1] Paul P, Chowdary KA, Shilotri M, Paul G, Degapudi M. A pelvic cauliflower-like growth: A misleading diagnosis. J South Asian Feder Obs Gynae. 2022;14(3):332-33.
[2] Tang YZ, Liyanage S, Narayanan P, Sahdev A, Sohaib A, Singh N, et al. The MRI features of histologically proven ovarian cystadenofibromas-an assessment of the morphological and enhancement patterns. Eur Radiol. 2013;23(1):48-56.
[3] Singh P, Gothwal M, Yadav G, Ghuman NK. Cystadenofibroma of ovary: A rare case report. J South Asian Feder Menopause Soc. 2019;7(2):94-96.
[4] Lee DH. A case of mucinous cystadenofibroma of the ovary. Case Rep Obstet Gynaecol. 2014;2014:130530.
[5] Dubey S, Kaushal A, Pavithra HN. Benign cystadenofibroma masquerading malignant tumour. J Med Sci. 2020;6(1):19-21.

PARTICULARS OF CONTRIBUTORS:

- 1. Junior Resident, Department of Radiodiagnosis, SRM Medical College Hospital and Research Centre, SRMIST, Chengalpattu, Tamil Nadu, India.
- 2. Junior Resident, Department of Radiodiagnosis, SRM Medical College Hospital and Research Centre, SRMIST, Chengalpattu, Tamil Nadu, India.
- 3. Junior Resident, Department of Radiodiagnosis, SRM Medical College Hospital and Research Centre, SRMIST, Chengalpattu, Tamil Nadu, India.
- 4. Professor and Head, Department of Radiodiagnosis, SRM Medical College Hospital and Research Centre, SRMIST, Chengalpattu, Tamil Nadu, India.

NAME, ADDRESS, E-MAIL ID OF THE CORRESPONDING AUTHOR:

Dr. Senthil Kumar Aiyappan,
Professor and Head, Department of Radiodiagnosis, SRM Medical College Hospital and Research Centre, Kattankulathur, Chengalpattu-603203, Tamil Nadu, India.
E-mail: asenthilkumarpgi@gmail.com

PLAGIARISM CHECKING METHODS: [Join H et al.]

- Plagiarism X-checker: Jul 08, 2024
- Manual Googling: Oct 08, 2024
- iThenticate Software: Oct 10, 2024 (15%)

ETYMOLOGY: Author Origin

EMENDATIONS: 5

AUTHOR DECLARATION:

- Financial or Other Competing Interests: None
- Was informed consent obtained from the subjects involved in the study? Yes
- For any images presented appropriate consent has been obtained from the subjects. Yes

Date of Submission: Jul 06, 2024
Date of Peer Review: Oct 03, 2024
Date of Acceptance: Oct 12, 2024
Date of Publishing: Jan 01, 2025